

Research Article

# Fluoroscopic Demonstration of Thoracic Tumor Immobilization with High Frequency Percussive Ventilation

Ina M Sala<sup>1,2\*</sup>, Beverly Maurer<sup>3</sup>, Cristian Solano<sup>4</sup>, Ronald Levitin<sup>1</sup> and Thomas M. Guerrero<sup>1,4</sup>

\*Corresponding author: Ina Marina Sala

Address: <sup>1</sup>Yale University School of Medicine, Department of Therapeutic Radiology, New Haven, CT, USA;

<sup>2</sup>Wayne State University School of Medicine, Karmanos Cancer Center, Detroit, MI, USA; <sup>3</sup>William Beaumont Hospital, Department of Pulmonary Physiology, Royal Oak, MI, USA; <sup>4</sup>Oakland University William Beaumont School of Medicine, Rochester, MI, USA

e-mail ✉ Ina.sala@yale.edu

Received: 27 October 2020; Accepted: 02 November 2020

## ABSTRACT

**Purpose:** The purpose of this first-in-man study is to directly measure thoracic tumor immobilization by high frequency percussive ventilation (HFPV).

**Methods:** In an IRB approved protocol (IRB # 2017-046) we screened patients with conspicuous lung tumors that exhibited motion >10 mm to undergo kV fluoroscopy with HFPV. Two sets of consecutive AP (anterior posterior) fluoroscopy frames were acquired during multiple breathing cycles for free- and HFPV- breathing. All images were acquired using our kV source/panel of the therapeutic linear accelerator. Percussions were delivered via the intrapulmonary percussive ventilation device (IPV-2C) and phasitron (Percussionaire Corp., Sagle, Idaho). The baseline settings for the IPV-2C (pressure, frequency, CPAP and inspiration time) were set during an initial training session, but minor adjustments were made prior to imaging at the direction and comfort of the patient.

**Results:** Patient recruited was a 69 y.o. female with stage IB (cT2a, cNo, cMo) adenocarcinoma of the LLL with lepidic and acinar growth pattern. She experienced slight discomfort lying flat on the treatment table, however successfully completed HFPV. Peak-to-peak tumor motion during 4DCT sim was 11.0 mm, however patient had already received 4x 10Gy fractions of SBRT when enrolled in the study, and therefore peak-to-peak motion during free-breathing measured with fluoroscopy, at the time of the study, was 6.2 mm. Subsequently, peak-to-peak motion measured with fluoroscopy during HFPV was at 2.7 mm. This resulted in a 57 % tumor motion reduction.

**Conclusion:** In this first-in-man study, we have shown that HFPV is a novel respiratory motion technique that can significantly reduce tumor motion.

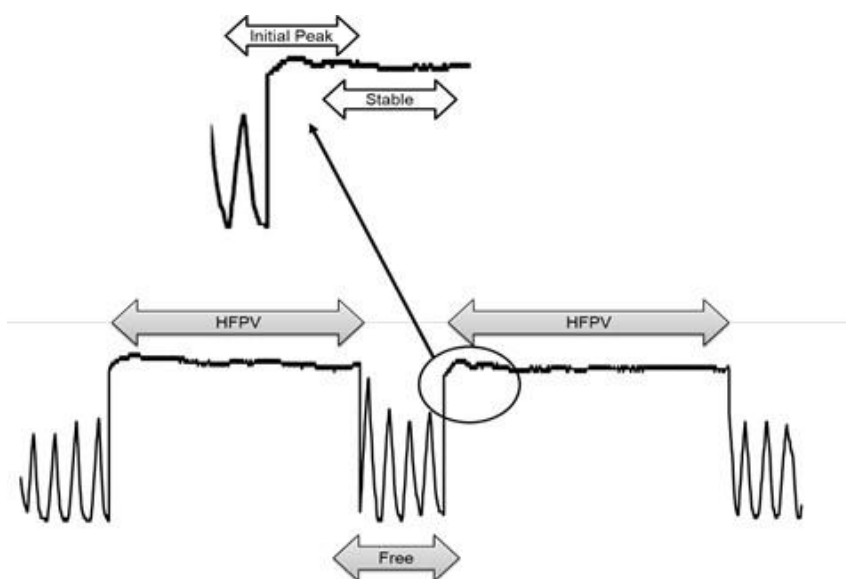
**Keywords:** HFPV, Tumor Motion Reduction, Respiratory Motion, First-In-Man, Direct Thoracic Tumor Immobilization, Percussive Ventilation

## Introduction

High frequency percussive ventilation (HFPV) is a novel immobilization technique that utilizes high frequency low tidal volume ventilation to produce endotracheal percussion (Salim and Martin, 2005; Allan *et al.*, 2010). The device is an adaptation of a pneumatic high frequency ventilator in which high flow jets of gas are delivered to the airways by a flow

interrupter called a Phasitron. Activation of the venturi system within the Phasitron creates bursts of gas at frequencies of 100 to 400 bursts per minute within a tightly controlled ratio of gas delivery and passive exhalation. The device is medically used for mobilization and clearance of pulmonary secretions. HFPV improves oxygenation versus conventional ventilation, with no barotrauma, in patients with acute respiratory distress syndrome (Spapen *et al.*, 2014; Gallagher *et al.*, 1989).

Previously, in an IRB approved study (IRB# 2017-046), we evaluated HFPV for chest wall motion immobilization (Sala *et al.*, 2019). We found volunteers tolerated the HFPV for varying lengths of time – from a few to tens of minutes. A sample trace of the thoracic wall motion from our study is shown in Fig. 1. In that study, we reported significant reduction in chest wall motion after initiation of percussive ventilation (mean: > 60%) as well as high duty cycle (mean: > 80%).



**Figure 1:** Sample trace of the thoracic wall motion. HFPV indicates the chest wall motion during HFPV and Free indicates the chest wall motion during free breathing as well as the initial peak at onset of HFPV

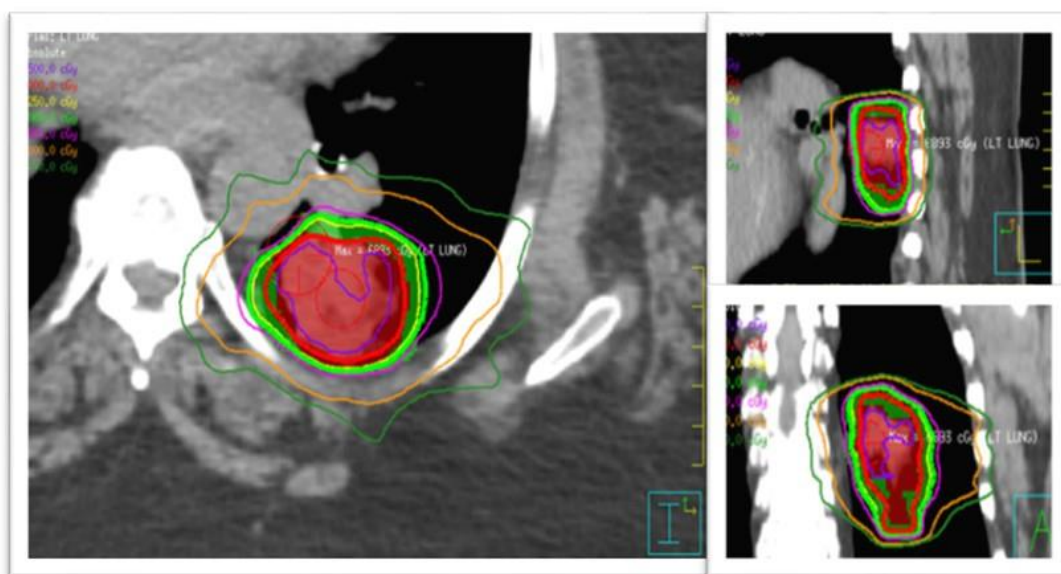
Recently, high frequency percussive ventilation (HFPV) was reported for immobilization of thoracic tumors for imaging (Prior, 2016) and stereotactic body radiotherapy (SBRT) (Peguret *et al.*, 2016). In Peguret's SBRT study, thoracic tumor respiratory motion was inferred from changes in the chest diameter measured by an Anzai respiratory belt (ANZAI Medical Co, Tokyo, Japan). There were patients who could not tolerate percussive ventilation assisted breath-holds for greater than 10 to 15 seconds. That preliminary study provided no direct evidence of tumor motion reduction. Filling this gap in knowledge is an important consideration before moving HFPV into clinical practice for tumor immobilization.

In this first-in-man clinical case study, we combined HFPV and fluoroscopy to directly visualize and quantify tumor motion.

## Material and Methods

### Patient Selection

Any patient with conspicuous (visible on projection x-ray, e.g. CT scout AP projection) lung tumors that exhibited  $\geq 10$  mm motion on their standard of care treatment planning 4DCT was recruited for this study. Between December 2018 and July 2019, we screened a total of 105 lung patients. Of which 27 had conspicuous tumors that moved  $>10$  mm. Of the twenty-seven, seven had COPD FEV<sub>1</sub> (Forced Expiratory Volume) score  $<50$  percentile which automatically excluded them from the study. One was under the age of 18, which also excluded them from the study. Eighteen declined for personal reasons. Only one patient accepted and underwent fluoroscopy with HFPV. The patient was a 69 year old female with Stage IB (cT2a, cN0, cM0) adenocarcinoma of the LLL (left lower lobe) with lepidic and acinar growth pattern (Fig. 2).



**Figure 2:** Tumor location

### Procedural Workflow

Prior to fluoroscopy, the patient underwent an initial 30-minute training session to become acclimated with the high frequency percussive ventilation technique. The patient was connected to the intrapulmonary percussive ventilation (IPV-2C) device (Percussionaire Corp., Sagle, Idaho) through the Phasitron and the Fischer & Paykel Oracle 452 CPAP (Fischer and Paykel Healthcare, Auckland, New Zealand) interface. The patient was then transferred to the treatment room where she was setup supine using her three-point isocenter tattoos with a cushion under her knees for comfort and arms above her head. We acquired two sets of consecutive fluoroscopy frames during multiple breathing cycles. One set was acquired while the patient was freely breathing and the other approximately 10 seconds post HFPV initiation. The settings of the Percussionaire IPV-2C (pressure, frequency, CPAP, inspiration time) were set by a certified respiratory therapist, but at the direction and comfort of the patient.

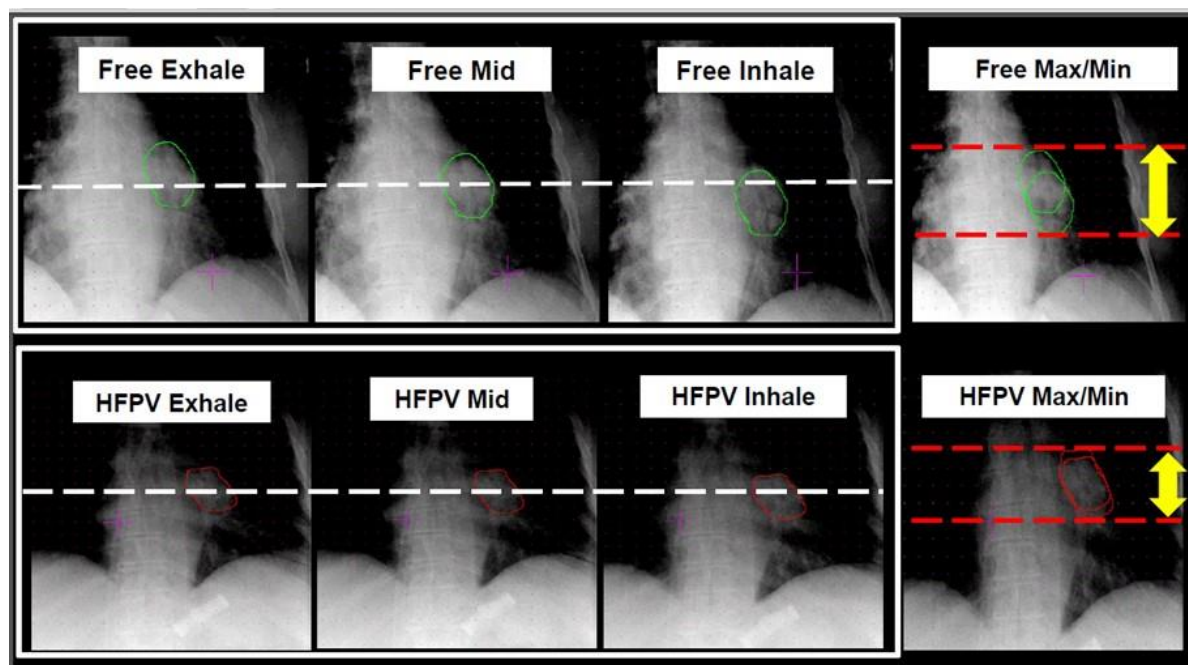
All fluoroscopy images were acquired in the AP (Anterior Posterior) direction with the gantry positioned at 270 degrees. Images were acquired with kV=120, mA=25, ms=40 and SFOV (Small Field of View) and a frame rate of 5.5 frames/second. The size of the images was 512x512x16bit with a Horizontal and Vertical resolution of 0.518 mm/pixel. Two points were selected in the target and traced along each fluoroscopy frame.

### Study Oversight

Patient was enrolled in the study following IRB approval (#2017\_046). Informed consent and authorization document specific to the study were provided and registration into the study was performed after the completion of pre-treatment evaluation and verification of the inclusion and exclusion criteria.

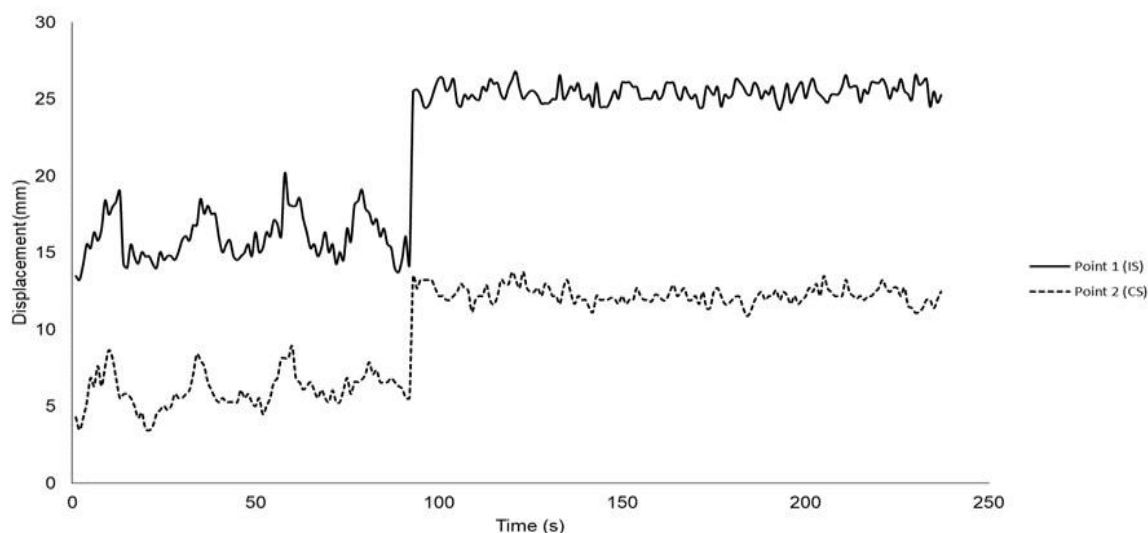
### Results

A total of 92 fluoroscopy frames were acquired while the patient was in free breathing and 147 in HFPV. Patient had prior history of COPD and was unable to tolerate a peak pressure higher than 12 cmH<sub>2</sub>O, whereas the healthy volunteers reported in our initial study (Sala *et al.*, 2019) tolerated between 20-22 cmH<sub>2</sub>O. A few of the fluoroscopy frames with contours of the tumor motion visualized during free- and HFPV breathing is shown in **Fig. 3**.



**Figure 3:** Green contour represent the target in free breathing and red in HFPV for inhale, mid and exhale position. Far right: overlay of the max and min contour for free-(green) and HFPV- (red) breathing.

A graph representation of points A and B traced along each frame is shown in **Fig. 4**. Time 0 to 100 represents target motion during free breathing and time 100 to 230 target motion during HFPV.



**Figure 4:** Direct Tumor Motion Graph. Point 1 and 2 represent two different points within the tumor.

The mean peak-to-peak motion for free breathing for both points was 6.2 mm (slightly lower than 11.0 mm measured during 4DCT). The mean peak-to-peak motion for HFPV breathing for both points was 2.7 mm. Therefore, the mean reduction in tumor motion while in HFPV, for both selected points, was at 57 %. The relative % reduction is comparable to the results found in our initial chest wall study (Sala *et al.*, 2019).

## Discussion

Providing consistent and direct tumor motion control is critical in escalating delivery doses, while maintaining good sparing of the healthy tissue. In this first-in-man study, we show a direct tumor motion reduction of 57 % that was consistently maintained for longer periods of time (minutes) than a typical breath-hold. Although patients last reported FEV1 score was in the normal range (>50 %), the patient had previous history of COPD which might have hampered our ability to maintain a pressure of 20 cmH<sub>2</sub>O, like that seen in our volunteer cohort (Sala *et al.*, 2019). However, even with the low peak pressure of 12 cmH<sub>2</sub>O motion was drastically reduced relative to patients' free breathing.

Tumor motion recorded during the 4DCT simulation was about 11.0 mm however; free breathing motion during fluoroscopy was approximately 6.2 mm. We attributed this difference to the 4x10 Gy SBRT fractions that the patient had already received as part of her care, prior to this fluoroscopy study. We believe that tumor size/motion might have changed from what was initially recorded during the 4DCT session.

In this study we did not evaluate prolonged HFPV times that the patient could've tolerated, but rather acquired several hundred fluoroscopic frames that would allow us to calculate direct tumor motion. Patient was however comfortable with the device and the length of time that she was in HFPV (~5 minutes).

During our volunteer study, it was noticed that some volunteers exhibited an initial peak at onset of HFPV as indicated in Fig. 1. The time between onset of HFPV and stable chest wall motion ranged between 3 to 6 seconds. As a result, in this study, we began imaging at least 10 seconds post start of HFPV.

To our knowledge, this is the first study to ever show direct tumor motion reduction using such a novel technique for radiotherapy. The drastic reduction of tumor motion, prolonged time, and other parameters measured in our initial study (Sala *et al.*, 2019), make HFPV a promising technique for respiratory motion management in radiotherapy, particularly for high risk cases like SBRT and cardiac arrhythmias like the study by Cuculich, *et al.* (2017).

## Conclusions

HFPV is a viable and novel technique that can be used for direct tumor immobilization. In this first ever study, we showed significant (~57%) tumor reduction relative to free breathing.

## Acknowledgments

Great appreciation to the patient enrolled in this study, the research team involved, and the clinical staff who referred this patient.

## References

Allan PF, Osborn EC, Chung KK, Wanek SM. High-frequency percussive ventilation revisited. *J Burn Care Res* 2010; 31: 510-520.

Cuculich PS, Schill MR, Kashani R, Mutic S, Lang A, Cooper D, Faddis M, Gleva M, Noheria A, Smith TW, Hallahan D. Noninvasive cardiac radiation for ablation of ventricular tachycardia. *New England Journal of Medicine* 2017; 377: 2325-2336.

Gallagher TJ, Boysen PG, Davidson DD, Miller JR, Leven SB. High-frequency percussive ventilation compared with conventional mechanical ventilation. *Critical Care Med* 1989; 17: 364-366.

Péguret N, Ozsahin M, Zeverino M, Belmondo B, Durham AD, Lovis A, Simons J, Long O, Duclos F, Prior J, Denys A. Apnea-like suppression of respiratory motion: First evaluation in radiotherapy. *Radiotherapy and Oncology* 2016; 118: 220-226.

Prior JO, Péguret N, Pomoni A, Pappon M, Zeverino M, Belmondo B, Lovis A, Ozsahin M, Vienne M, Bourhis J. Reduction of respiratory motion during PET/CT by pulsatile-flow ventilation: a first clinical evaluation. *Journal of Nuclear Medicine* 2016; 57: 416-419.

Reardon CC, Christiansen D, Barnett ED, Cabral HJ. Intrapulmonary percussive ventilation vs incentive spirometry for children with neuromuscular disease. *Arch Pediatric Adolescent Medicine* 2005; 159: 526-531.

Sala IM, Nair GB, Maurer B, Guerrero TM. High frequency percussive ventilation for respiratory immobilization in radiotherapy. *Technical Innovations & Patient Support in Radiation Oncology* 2019; 9: 8-12.

Salim A and Martin M. High-frequency percussive ventilation. *Critical Care Med* 2005; 33: S241-S245.

Spapen H, Borremans M, Diltoer M, Van Gorp V, Nguyen DN, Honoré PM. High-frequency percussive ventilation in severe acute respiratory distress syndrome: A single center experience. *Journal of Anaesthesiology Clinical Pharmacology* 2014; 30: 65-70.